GIANT PENDULUM WDLS THROUGH SCIATIC NOTCH: TRANSIENT ILIAC OSTEOTOMY FOR COMPLETE TUMOR RESECTION

PASCAL C. HAEFELI[2], CARMEN HUEMMER[2], JÜRG METZGER[2], MARTIN BECK[2], BRUNO FUCHS[1-4]
Sarcoma Service
Cantonal Hospitals Winterthur[1]/Luzern[2] , University Hospital[3] / Kinderspital Zurich[4]
www.SARCOMA.SURGERY / www.SWISS-SARCOMA.NET

INTRODUCTION

Pendulum tumors around the pelvis are infrequent, occur per definition intra- and extrapelvically, and pass either through the sciatic notch or the foramen obturatorium. Most often, there is a large discrepancy between the two parts of the tumor such, that the entirety of the mass can be approached from one compartment. However, if both the intra- and extrapelvic parts are so large that this is not possible, the question remains how to approach. Specifically, when the tumor should be removed completely for oncologic purposes.

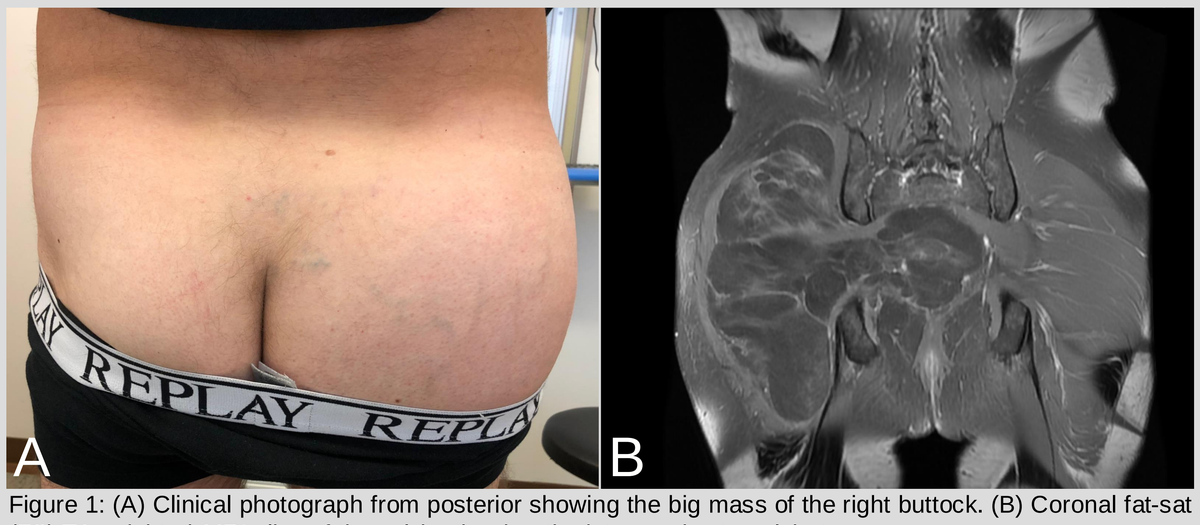

Figure 1: (A) Clinical photograph from posterior showing the big mass of the right buttock. (B) Coronal fat-sat (FS) T1 weighted MRI slice of the pelvis showing the intra- and extrapelvic tumor mass.

PATIENT & METHODS

A 45 year old man noticed some unspecific abdominal pain for years, as well as right gluteal swelling for some months, but when a foot drop occurred, he sought medical attention. A large lipomatous tumor mass of 38cm in diameter was found on imaging both intra- and extrapelvically, communicating through the sciatic notch, and involving all the sacral nerve roots on the right side which were entirely looped within the tumor mass. Ultrasound-guided tru-cut biopsy revealed a well differentiated liposarcoma, whereas some dedifferentiated parts with this large mass were still possible. To potentially improve the intrapelvic resection margins, preoperative radiotherapy with 50Gy was administered.

RESULTS

Using a triradiate incision, both intra- and extrapelvic masses were dissected, and to remove the mass in its entirety, we elected to osteotomize the ilium starting from the posterior aspect of the notch, slightly anteriorly tilted. The roof of the notch was separately removed with some 2x3cm, rendering an iliac opening (together with moving the leg) of up to 6cm, thereby allowing to lift the entire tumor in one piece. The sacro-spinal and –tuberal ligaments were preserved, as well as the femoral and obturator nerves, while all the ipsilateral sacral nerve roots were sacrificed. The pelvic osteotomy was refixated using three threaded screws. This patient developed local wound healing problems necessitating a local rectus abdominis-perforator flap. Five months postoperatively, the patient is ambulatory with crutches.

CONCLUSION

An intra- and extrapelvic tumor mass - which for oncologic reasons has to be completely removed - is safely approached through an iliac osteotomy, allowing to open up wide enough to mobilize it en bloc. Anatomic reduction is followed by screw osteosnythesis, and no additional morbidity is expected.

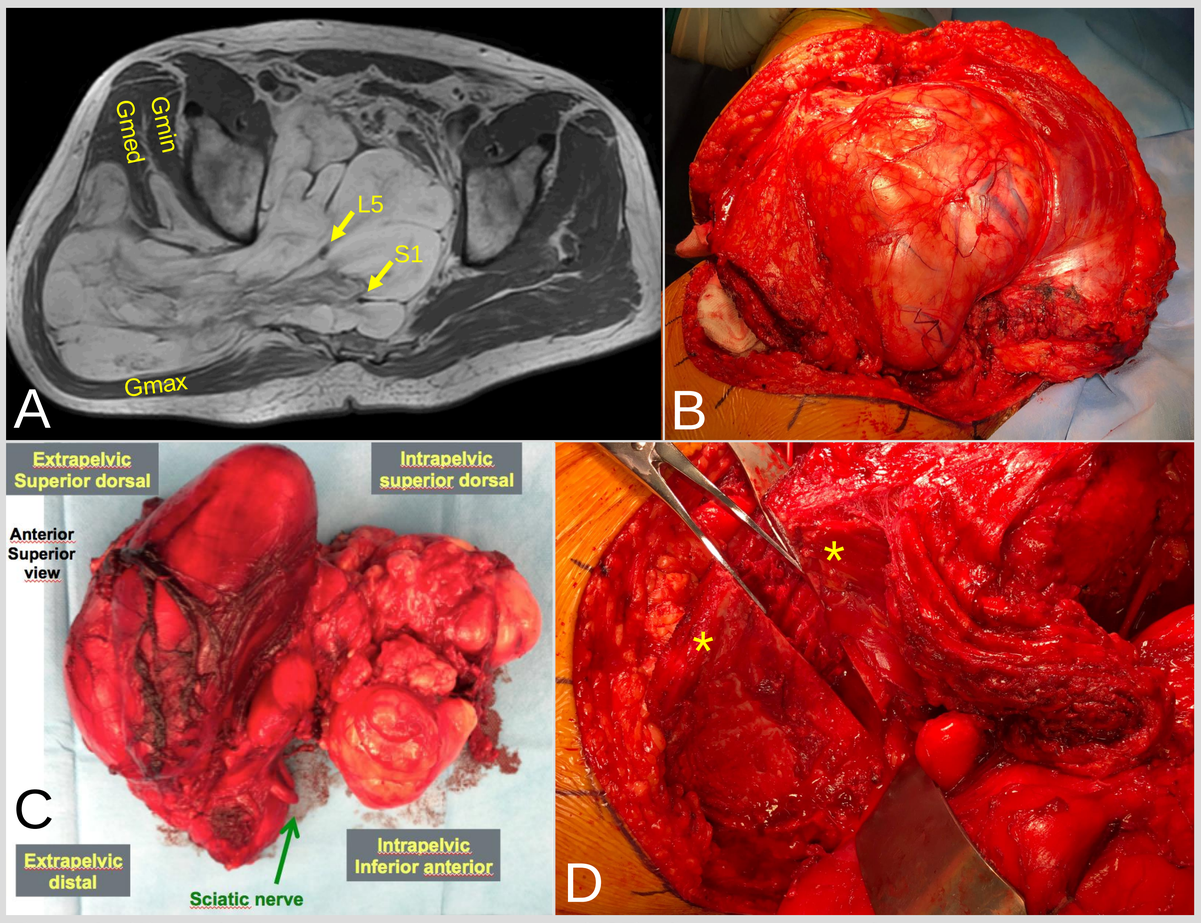

Figure 2: (A) Axial T1-weighted turbo spin echo (TSE) slice showing the fatty tumor growing into the intermuscular intervals of the gluteals (Gmin, med and max), passing through the sciatic notch into the pelvis and enclosing the nerve roots (arrows). (B) Intraoperative photograph of the tumor in situ from lateral, in the left lower corner the iliac crest is shown. (C) Photograph of the completely excised tumor, proximally the right-sided nerve roots L5 to S5 and distally the iliac nerve had to be transected due to remove the tumor in ist entirety. (D) Intraoperative photography showing the iliac crest and wing after disection of the gluteus minimus and medius. To remove the entire tumor in one piece the ilium was transected and is splayed with a AO distractor.

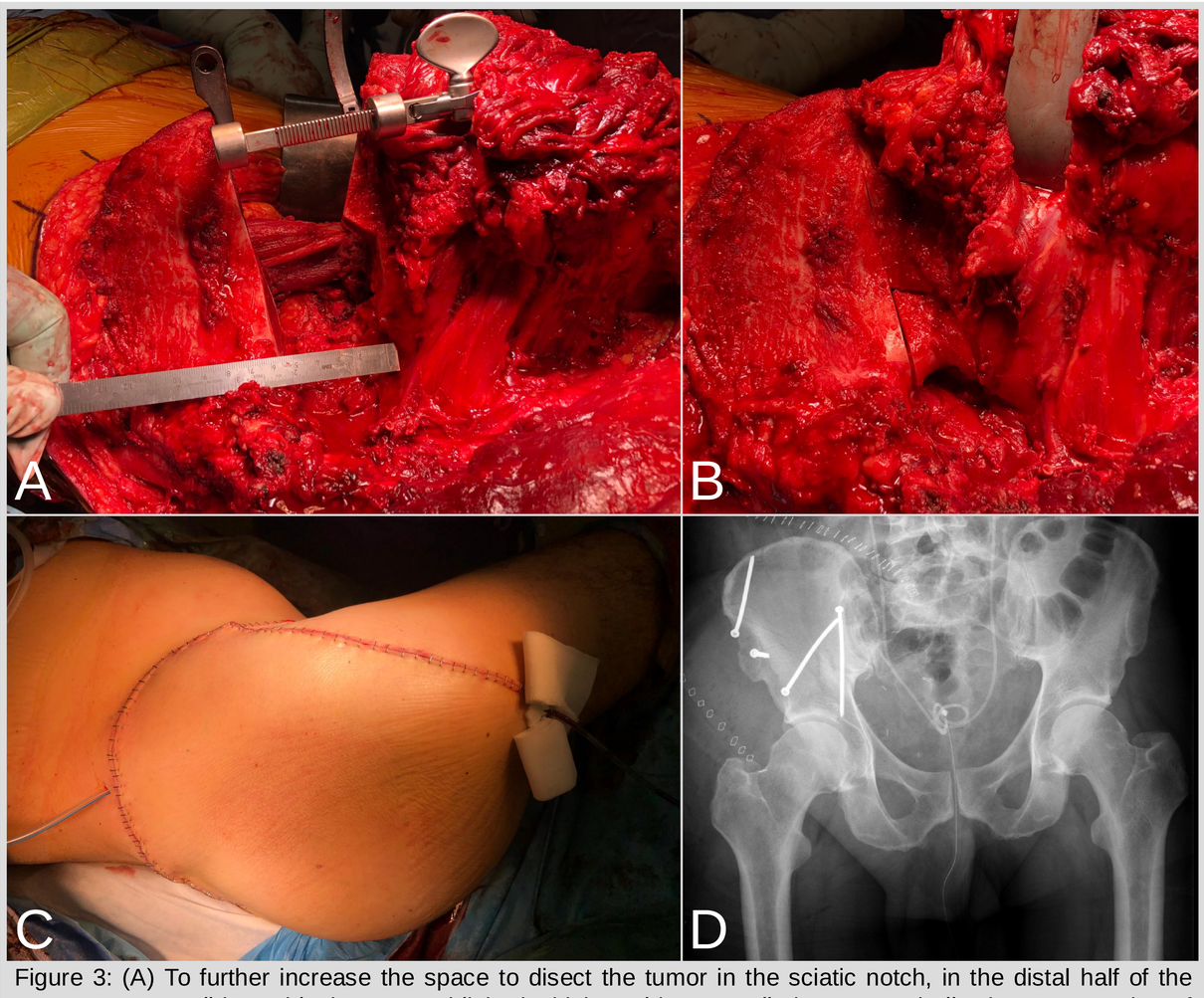

Figure 3: (A) To further increase the space to disect the tumor in the sciatic notch, in the distal half of the osteotomy a small bone block was established which could temporally be removed allowing preservation of the entirety of the tumor during removal. The bone block could be reduced and fixated with one postero-anterior screw (B). (C) Postoperative photography showing the sutured incision and two of three wound drains. (D) Postoperative antero-posterior radiograph shows the screw refixation of the osteotomized ilium.

HIGHLIGHTS:

Six months postoperatively, this 45 year old patient walks 5km without pain and without support nor any restriction despite removal of the entire anterior pelvis.

SWISS SARCOMA NETWORK

KSW KANTONSSPITAL WINTERTHUR

luzerner kantonsspital

SarcOmaSurgery